

Thieme Group

MedOne Platform



Thieme

Uwe Stehle

Senior Sales Manager
Institutional Sales
uwe.stehle@thieme.de
0049 711 8931 939

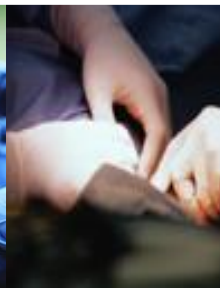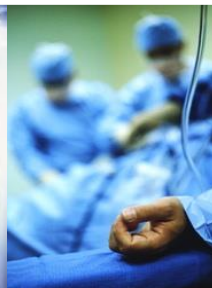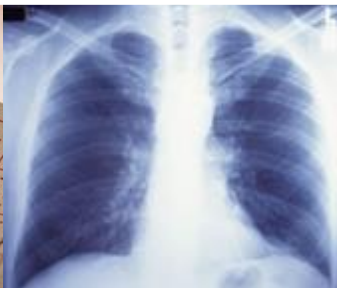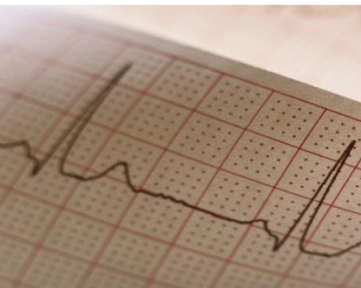
Over 130 years of expertise

German Publisher

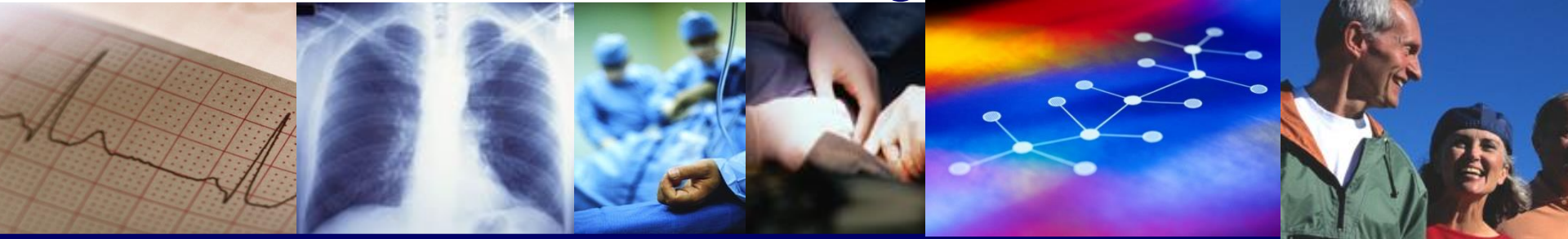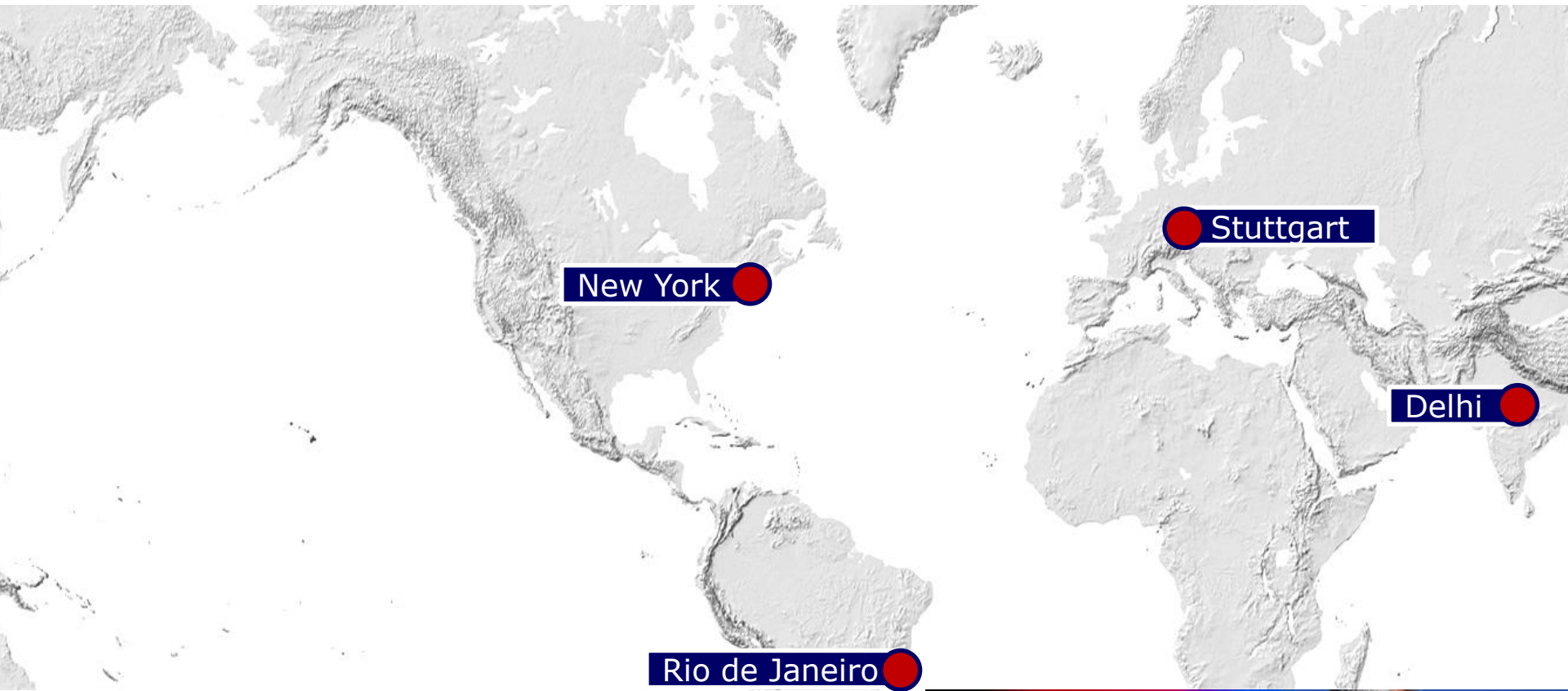Founded in 1886 by Georg Thieme

Still family owned

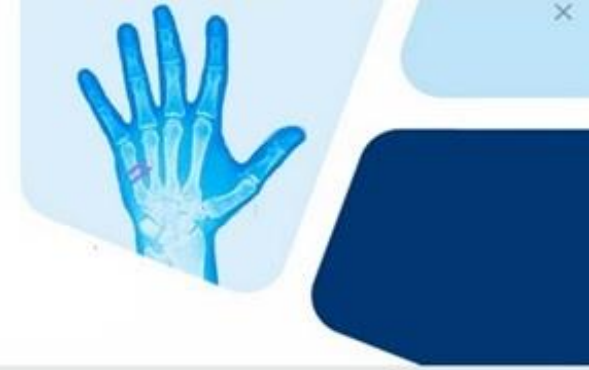Global market leader in Neurosurgery and
Otolaryngology



Over 130 years of expertise



Welcome to **MedOne**



**New platform combining
Thieme content from all media
for clinical specialties, like**

- **Radiology**
- **Neurosurgery**
- **Plastic Surgery**
- **Communication Science**
- **Otolaryngology**
- **and more to come**

Home My MedOne

Searching in E-Books

Search

> Login > Sign up for access from home

> Enter access code > Further subject areas

Your filters: x E-Books

Search and read E-Books

Please filter:

Sub-Topic

Title

Author / Editor

A - Z

Publication date

SOURCES / CONTENT

E-Books

RadCases




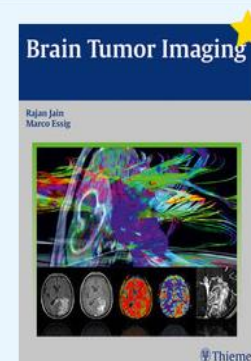

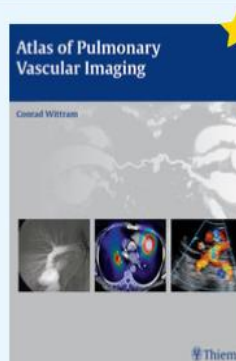
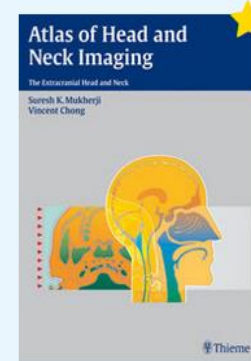
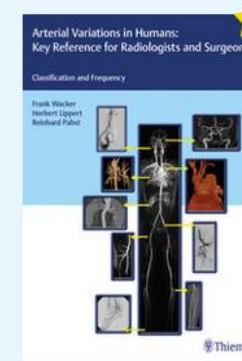
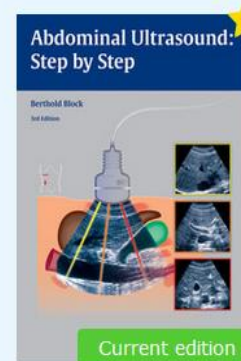
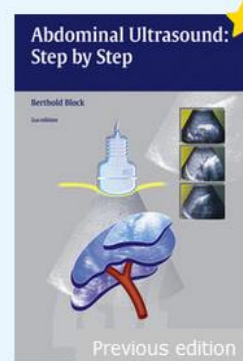

E-Journals

Media

Playlists

SUBJECT AREAS

Remove all filters



Home

My MedOne

Searching in E-Books

Search

> Login > Sign up for access from home

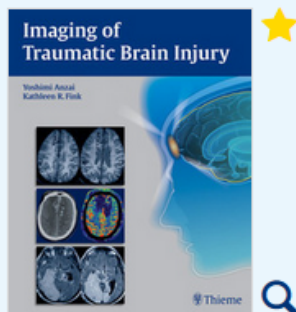
> Enter access code > Further subject areas

<< Back to overview

Yoshimi Anzai, Kathleen R. Tozer-Fink

Imaging of Traumatic Brain Injury

TOC, images and hits in separate tabs



Source: [Anzai Y, Tozer-Fink K, Hrsg.](#) 1st Edition. Thieme; 2015.

Content

Images

Hits

- + Epidemiology of Traumatic Brain Injuries in the United States
- + Evidence-Based Imaging and Prediction Rules: Who Should Get Imaging for Mild Traumatic Brain Injury?
- **Neuroimaging of Traumatic Brain Injury**

Introduction

Imaging Workups for Traumatic Brain Injury

Prediction of Clinical Outcomes

Imaging Findings of Primary

brain injury

Neuroimaging of Traumatic Brain Injury

Neuroimaging of Traumatic Brain Injury

Yoshimi Anzai

Quick access

Introduction|Imaging Workups for Traumatic [Brain Injury](#)|Prediction of Clinical Outcomes|Imaging Findings of Primary Traumatic [Brain Injury](#) Lesions|Pearls|References

Introduction

Traumatic [brain injury](#) (TBI) is a major public health and socioeconomic problem in the United States and throughout the world. The U.S. Centers for Disease Control and Prevention estimates that approximately 1.7 million Americans sustain a TBI annually, resulting in 1.3 million visits to the emergency department, 275,000 hospitalizations, and more than 50,000 deaths related to TBI annually.¹ Clearly, TBI is a leading cause of death among young adults in the United States. These numbers underestimate the actual magnitude of TBI because the statistics are unknown for those who do not seek medical care or who have no access to care. Moreover, long-term disability as a result of TBI is being increasingly recognized as a public health issue. It is estimated that at least 5.3 million Americans (up to 2% of the U.S. population) suffer from long-term or lifelong disability as a result of TBI.²

The common causes of TBI are falls, motor-vehicle crashes, bike accidents, sports-related injuries, assault and battery, and most recently blast injuries among soldiers returning from the Iraq and Afghanistan wars.³ In Seattle, a city of motorcycle and bicycle enthusiasts, accidents are frequent and occasionally fatal among youth, despite mandatory bicycle-helmet-use laws in King County and Washington State.⁴

The vast majority of sports-related TBIs are so-called mild traumatic [brain injury](#) (mTBI), or concussion.⁵ Concussion presents unique features of TBI in which emotional and behavioral psychological symptoms persist in some of the victims. Conventional imaging does not usually demonstrate abnormality, and advanced imaging has been tested with variable results. This topic is discussed in detail in Chapter 11 of this book.

Home

My MedOne

Searching in E-Books

Search

> Login > Sign up for access from home

> Enter access code > Further subject areas

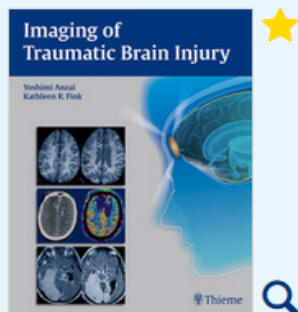
<< Back to overview

PDF

∞

Yoshimi Anzai, Kathleen R. Tozer-Fink

Imaging of Traumatic Brain Injury

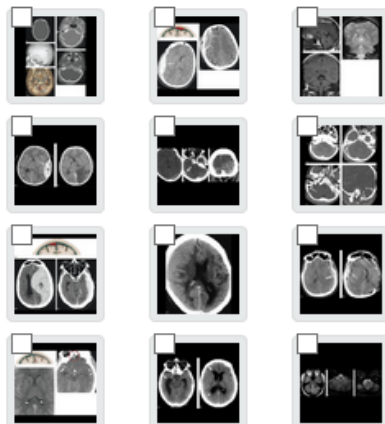


Source: [Anzai Y, Tozer-Fink K, Hrsg.](#)
1st Edition. Thieme; 2015.

Content

Images

Hits



brain injury



Neuroimaging of Traumatic Brain Injury

Neuroimaging of Traumatic Brain Injury

Yoshimi Anzai

Quick access

Introduction|Imaging Workups for Traumatic [Brain Injury](#)|Prediction of Clinical Outcomes|Imaging Findings of Primary Traumatic [Brain Injury](#)
Lesions|Pearls|References

Introduction

Traumatic [brain injury](#) (TBI) is a major public health and socioeconomic problem in the United States and throughout the world. The U.S. Centers for Disease Control and Prevention estimates that approximately 1.7 million Americans sustain a TBI annually, resulting in 1.3 million visits to the emergency department, 275,000 hospitalizations, and more than 50,000 deaths related to TBI annually.¹ Clearly, TBI is a leading cause of death among young adults in the United States. These numbers underestimate the actual magnitude of TBI because the statistics are unknown for those who do not seek medical care or who have no access to care. Moreover, long-term disability as a result of TBI is being increasingly recognized as a public health issue. It is estimated that at least 5.3 million Americans (up to 2% of the U.S. population) suffer from long-term or lifelong disability as a result of TBI.²

The common causes of TBI are falls, motor-vehicle crashes, bike accidents, sports-related injuries, assault and battery, and most recently blast injuries among soldiers returning from the Iraq and Afghanistan wars.³ In Seattle, a city of motorcycle and bicycle enthusiasts, accidents are frequent and occasionally fatal among youth, despite mandatory bicycle-helmet-use laws in King County and Washington State.⁴

The vast majority of sports-related TBIs are so-called mild traumatic [brain injury](#) (mTBI), or concussion.⁵ Concussion presents unique features of TBI in which emotional and behavioral psychological symptoms persist in some of the victims. Conventional imaging does not usually demonstrate abnormality, and advanced imaging has been tested with variable results. This topic is discussed in detail in Chapter 11 of this book.

Home

My MedOne

Searching in E-Books

Search

> Login > Sign up for access from home

> Enter access code > Further subject areas

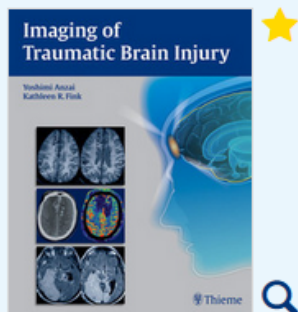
<< Back to overview

PDF

∞

Yoshimi Anzai, Kathleen R. Tozer-Fink

Imaging of Traumatic Brain Injury



Source: [Anzai Y, Tozer-Fink K, Hrsg.](#) 1st Edition. Thieme; 2015.

Content

Images

Hits

Underlying Causes of Traumatic Brain Injury

Mild Traumatic Brain Injury

Secondary Brain Injury

Pathophysiology of Traumatic Brain Injury and Impact on Management

Physiologic Monitoring for Traumatic Brain Injury Patients

Advanced Imaging in Mild Traumatic Brain Injury and Concussion

brain injury



Neuroimaging of Traumatic Brain Injury

Neuroimaging of Traumatic Brain Injury

Yoshimi Anzai

Quick access

Introduction|Imaging Workups for Traumatic [Brain Injury](#)|Prediction of Clinical Outcomes|Imaging Findings of Primary Traumatic [Brain Injury](#) Lesions|Pearls|References

Introduction

Traumatic [brain injury](#) (TBI) is a major public health and socioeconomic problem in the United States and throughout the world. The U.S. Centers for Disease Control and Prevention estimates that approximately 1.7 million Americans sustain a TBI annually, resulting in 1.3 million visits to the emergency department, 275,000 hospitalizations, and more than 50,000 deaths related to TBI annually.¹ Clearly, TBI is a leading cause of death among young adults in the United States. These numbers underestimate the actual magnitude of TBI because the statistics are unknown for those who do not seek medical care or who have no access to care. Moreover, long-term disability as a result of TBI is being increasingly recognized as a public health issue. It is estimated that at least 5.3 million Americans (up to 2% of the U.S. population) suffer from long-term or lifelong disability as a result of TBI.²

The common causes of TBI are falls, motor-vehicle crashes, bike accidents, sports-related injuries, assault and battery, and most recently blast injuries among soldiers returning from the Iraq and Afghanistan wars.³ In Seattle, a city of motorcycle and bicycle enthusiasts, accidents are frequent and occasionally fatal among youth, despite mandatory bicycle-helmet-use laws in King County and Washington State.⁴

The vast majority of sports-related TBIs are so-called mild traumatic [brain injury](#) (mTBI), or concussion.⁵ Concussion presents unique features of TBI in which emotional and behavioral psychological symptoms persist in some of the victims. Conventional imaging does not usually demonstrate abnormality, and advanced imaging has been tested with variable results. This topic is discussed in detail in Chapter 11 of this book.

Home

My MedOne

Searching in E-Journals

Search

> Login > Sign up for access from home

> Enter access code > Further subject areas

Your filters: **x E-Journals**

Read E-Journals

Please filter:

Title

Year

Issue

Volumes

Article type

Name

Publication date

SOURCES / CONTENT

E-Books

Procedures

Learn from the Masters

E-Journals

Media

Training Center

Playlists

SUBJECT AREAS

 Remove all filters

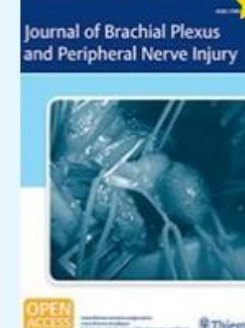
Archive



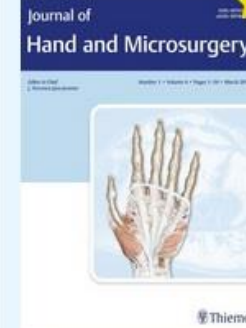Archive



Archive



Archive



Archive



Archive

No additional entries available

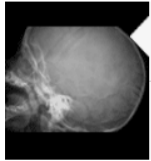
[Home](#)[My MedOne](#)

Searching in E-Books

Search

[> Login](#) [> Sign up for access from home](#)[> Enter access code](#) [> Further subject areas](#)

Work Case Studies

[Case Viewer](#)[Feedback](#)

ip172.20.15.2

[+ New Cases](#)3449
NEW2
REVISIT2
MASTERED3453
TOTAL CASES

As of today, you are subscribed to total of **3453** cases. The more cases you have, the better prepared you will be. To benefit fully from **RadCases** click on the "+ New Cases" button to enhance your access with even more carefully selected, must-know cases.

To begin using the Case Viewer, please select from one of the viewing mode choices below.

Which viewing mode do you prefer?

**resume session**

Resume looking at the cases I selected during my previous session.

**view random**

Access a random selection of 100 *NEW* cases drawn from my *SUBSCRIBED* cases.

**search my cases**

Search for all types of cases filtered by selected options, i.e. sex, age, system, modality, etc.

**select by case number**

Select cases by case number or range of numbers.



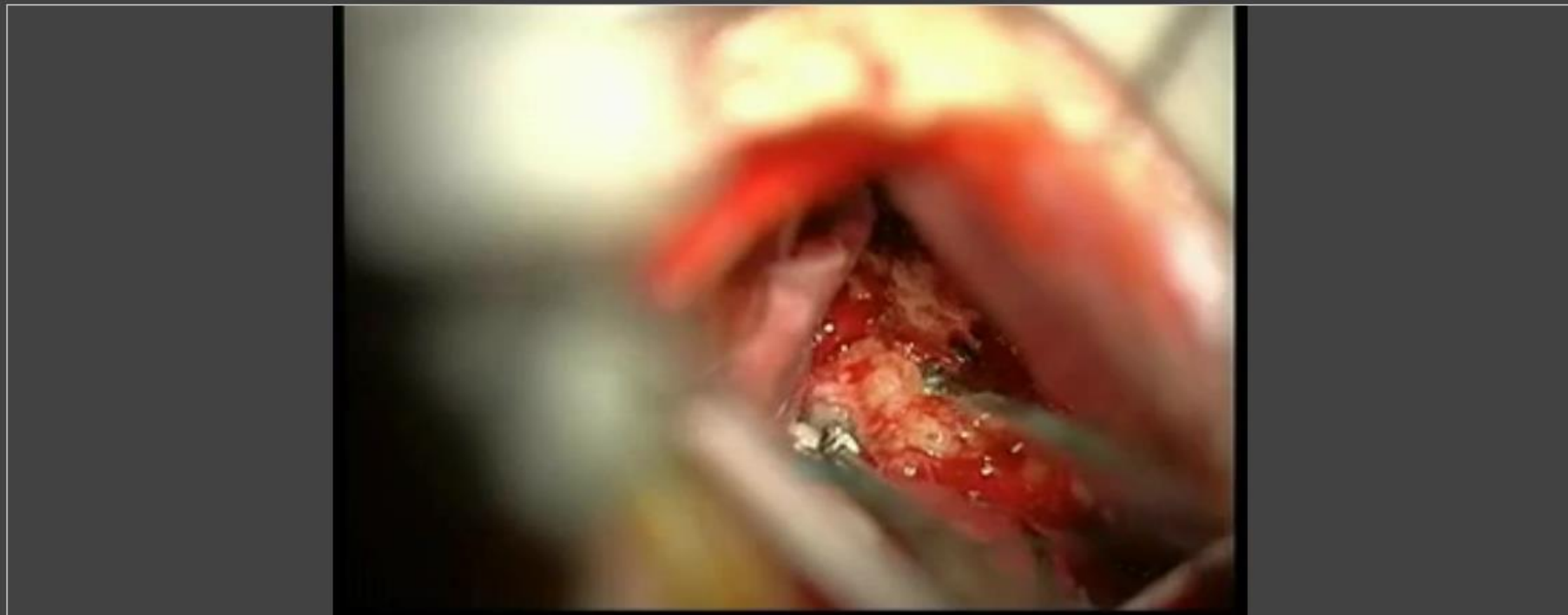
[Home](#)[My MedOne](#)

Searching in Media

Search

[> Login](#) [> Sign up for access from home](#)[> Enter access code](#) [> Further subject areas](#)[« Back to overview](#)

Watch videos

MODALITY **All**AUDIO/IMAGE/VIDEO **All** Video

Video 17.34 [Video 10.1] Tuberculoma meningioma resected via the eyebrow approach.

Source: Chapter 10. In: Teo C, Sughrue M, Hrsg. Principles and Practice of Keyhole Brain Surgery. 1st Edition. Thieme; 2015.

Home

My MedOne

brain injury

Search

> Login > Sign up for access from home

> Enter access code > Further subject areas

Your search: brain injury

Your filters: Media

Search and select images

Please filter:

Audio/Image/Video

Date

Relevance

SOURCES / CONTENT

Media 309 results for "brain injury"



E-Books

E-Journals

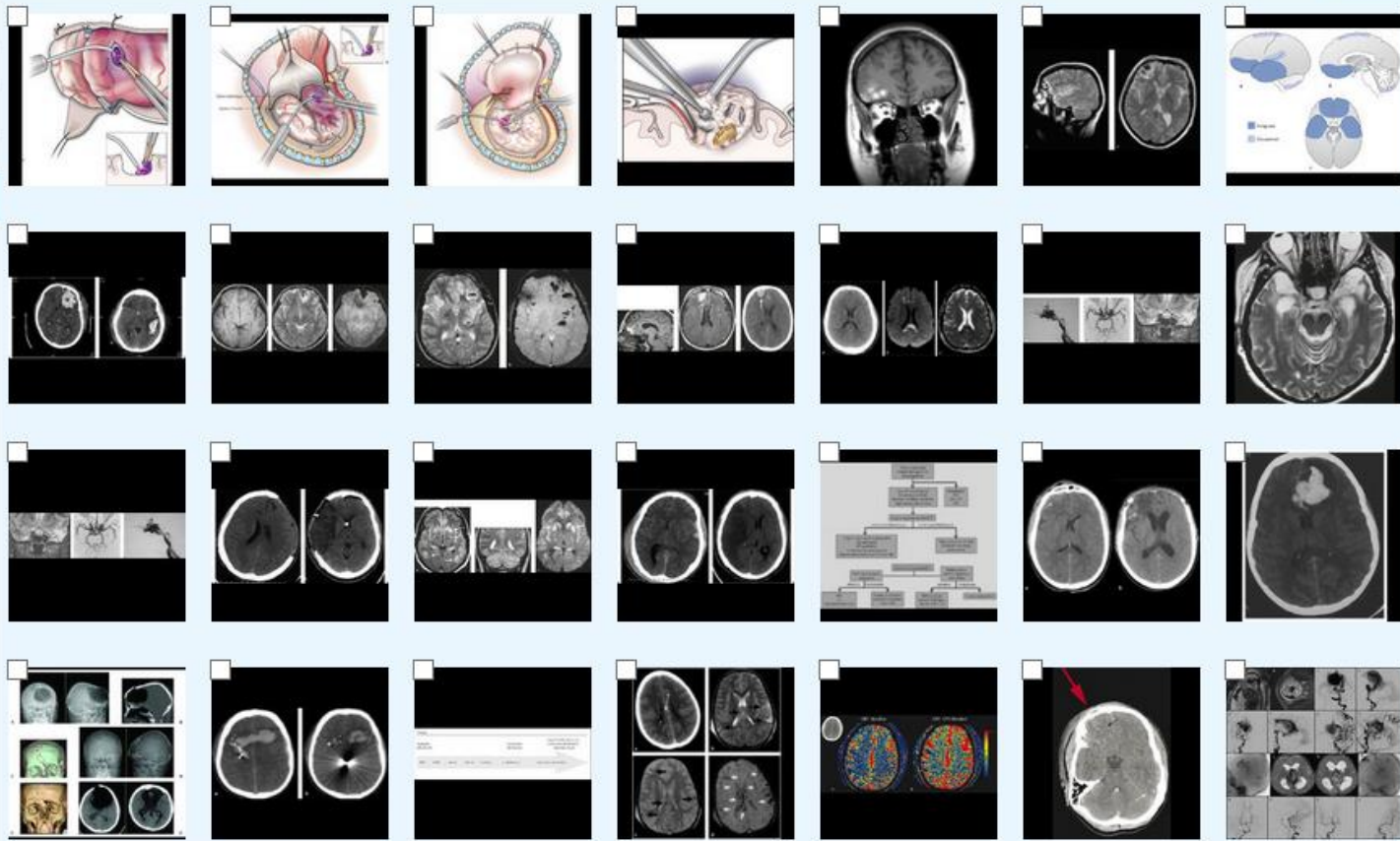
Media

Training Center

Playlists

SUBJECT AREAS

Remove all filters



Home

My MedOne

Searching in Media

Search

> Login > Sign up for access from home

> Enter access code > Further subject areas

<< Back to overview



MODALITY All

AUDIO/IMAGE/VIDEO All Image Video

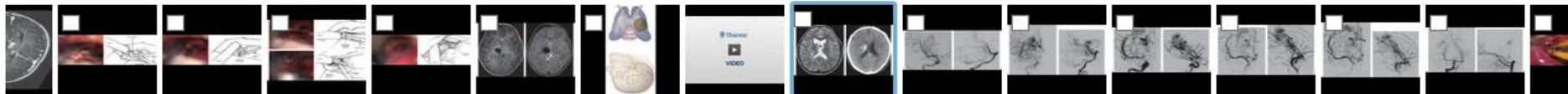
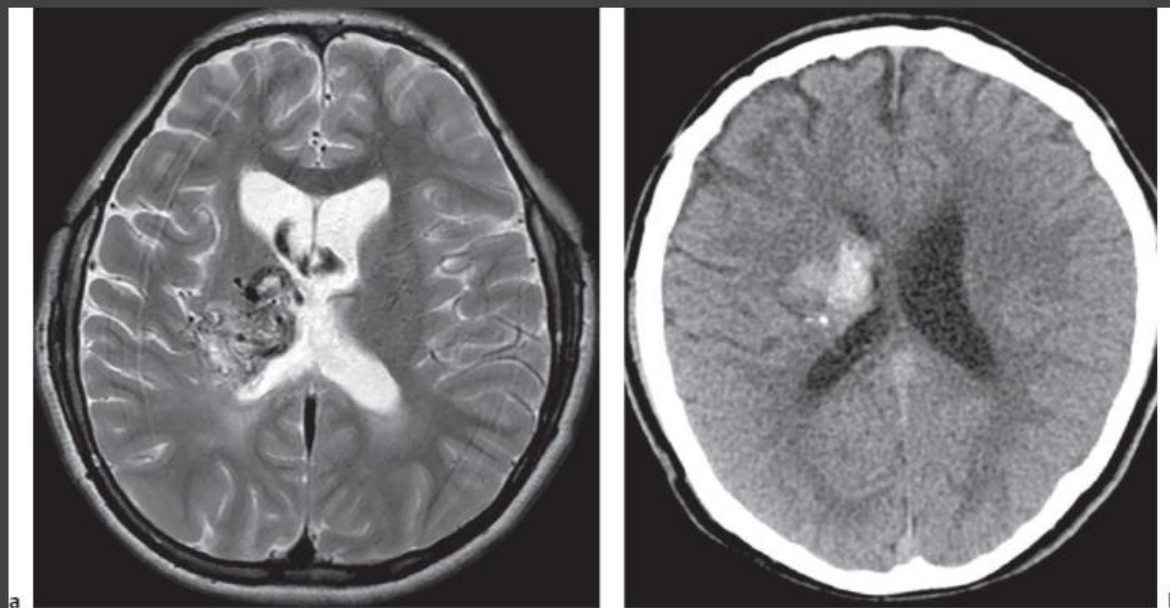
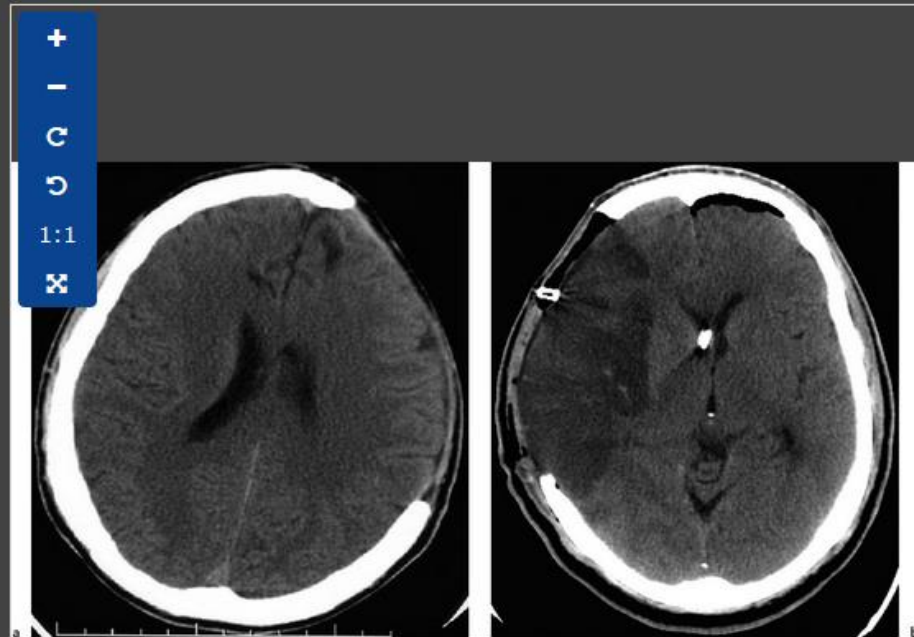
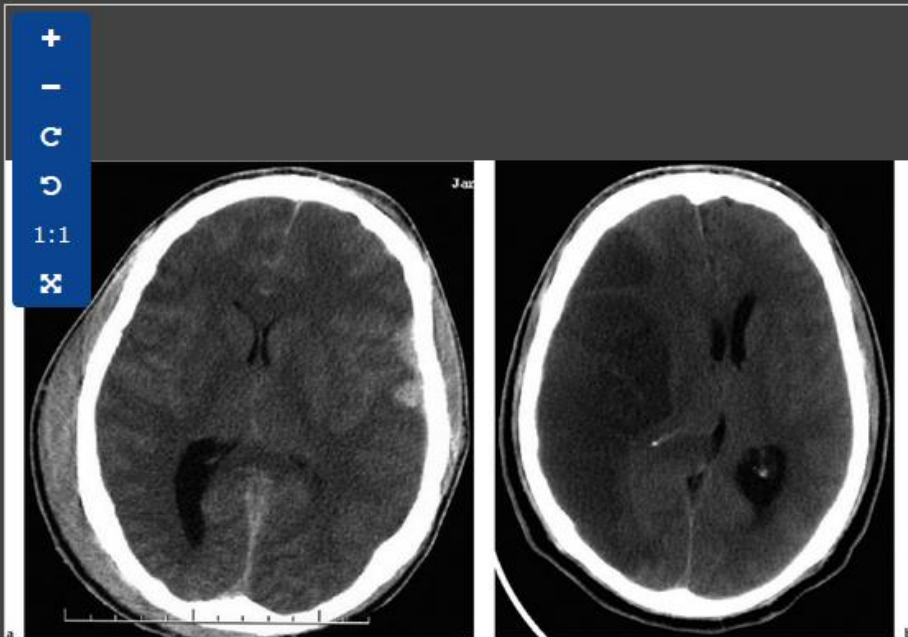
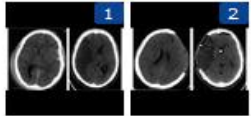
+
-
C
↶
↷
1:1
✕

Figure 5.12. (a) Axial T2-weighted magnetic resonance image demonstrates flow voids in the right thalamus of a 13-year-old patient consistent with a history of a thalamic

compare images

Image comparison

SELECTED FOR COMPARISON:



[Home](#)[My MedOne](#)

Searching

Search

[> Login](#) [> Sign up for access from home](#)[> Enter access code](#) [> Further subject areas](#)[Back to overview](#)[Introduction](#)

Access the training centre for Q&A

1518 /2387



Question



Answer

Question 1518

Complete the following:

- What must you look for in a patient with a major spinal injury?
- It occurs in _____%.

Correctly answered repeat[← Previous question](#)[Next question →](#)

Source:

Introduction

From: [Leonard I. Kratzler](#), [Jonathan G. Hobbs](#): The Greenberg Rapid Review: A Companion to the 8th EditionShort link: <https://medone-neurosurgery.thieme.com/ULYDF>

[Home](#)[My MedOne](#)

Searching

Search

[> Login](#) [> Sign up for access from home](#)[> Enter access code](#) [> Further subject areas](#)[Back to overview](#)

Introduction

[Statistics of learning progress](#)

1518 /2387



Question



Answer

Answer

Complete the following:Greenberg 8th edition,
Chapter 62.1

- | | |
|--|------------------------|
| a. What must you look for in a patient with a major spinal injury? | a second spinal injury |
| b. It occurs in _____%. | 20% |

Correctly answered repeat[← Previous question](#)[Next question →](#)

Source:

Introduction

From: [Leonard I. Kratzler](#), [Jonathan G. Hobbs](#): The Greenberg Rapid Review: A Companion to the 8th EditionShort link: <https://medone-neurosurgerv.thieme.com/ULYDF>

Home

My MedOne

Searching

Search

> Login > Sign up for access from home

> Enter access code > Further subject areas

Your filters: Public playlists

Please filter:

Public play

SOURCES / CONTENT

Please apply filter...

Create new playlist

E-Books

Cases

E-Journals

Media


Playlists

SUBJECT AREAS

 Remove all filtersPlaylist Anatomy and
Physiology of
Speech and
Hearing

MedOne Team


7 items

Playlist 

Aphasia


MedOne Team

8 items

Playlist How to Create a
MedOne ComSci
Playlist

MedOne Team

1 item

Playlist 

Vestibular

MedOne Team

13 items

No additional entries available

„Playlists“ allow creation of personal
info packages

[Home](#)[My MedOne](#)

Searching

Search

[> Login](#) [> Sign up for access from home](#)[> Enter access code](#) [> Further subject areas](#)

Playlist created by: MedOne Team

Aphasia SLPPlaylist 

Aphasia

MedOne Team

8 items


Create playlists for personal use or share with colleagues/students

Search Within this Playlist

**Assessment and Management of Aphasia**

Assessment and Management of Aphasia

Source: Johnson A, Jacobson B, Hrsg. Medical Speech-Language Pathology. A Practitioner's Guide. 3rd Edition. Thieme; 2016.

 Chapter from Johnson's Medical Speech-Language Pathology, 3/e

SLP

Script Training in a Case of Nonfluent/Agrammatic-Primary Progressive AphasiaCase (1)

SLP

Aphasia and Dysphagia in a Resident of a Skilled Nursing FacilityCase (1)

SLP

Compensatory and Restorative Application of AAC in Chronic, Severe AphasiaCase (1)

SLP

A Case of Stroke-Induced, Moderate, Acquired Apraxia of Speech and Nonfluent AphasiaCase (1)

SLP

Speech Therapy Telepractice Program for a Client with AphasiaCase (1)

Welcome to MedOne



Further options

- **Download images directly to powerpoint**
- **Download e-book chapters as pdf**
- **Download journal articles as pdf**
- **Set up „access from home“**
- **Create and share „playlists“ (public or private)**
- **Use mobile access**



Mac

iPad

iPhone

Watch

TV

Music

Support



App Store Preview

This app is only available on the App Store for iOS devices.

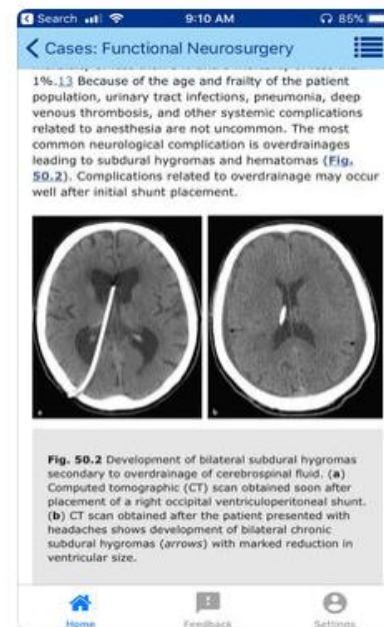
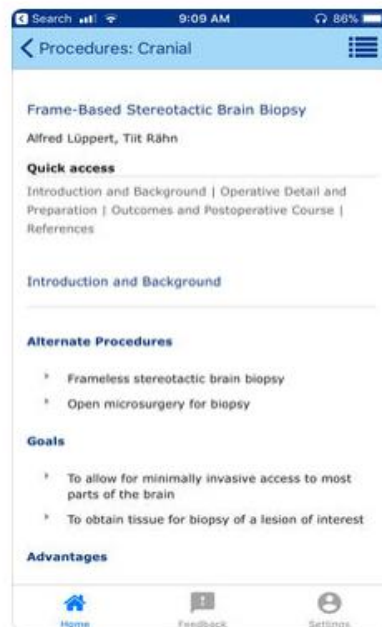
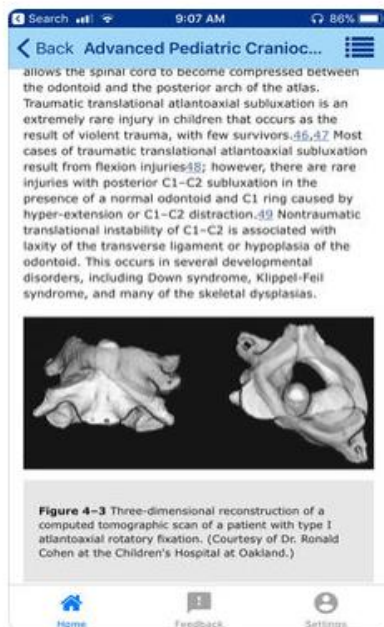
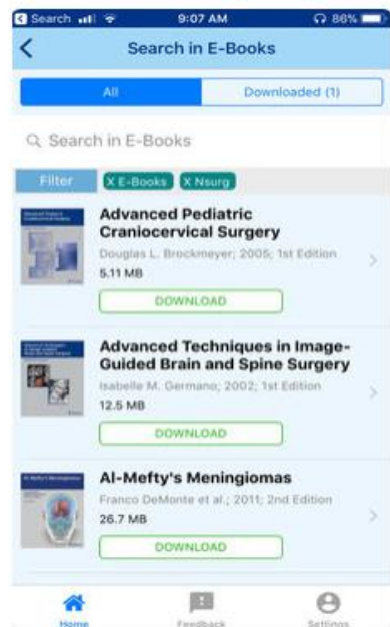


MedOne 17+

Thieme Publishers

Free

Screenshots iPhone iPad



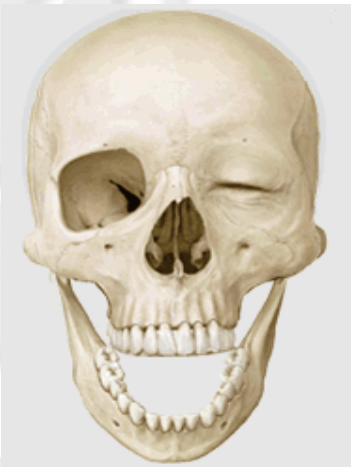Welcome to **MedOne**



**Request a free trial access
with Shibboleth or IP authentication
at any time**

Do you have any questions?

Thank you very much for your interest.



Uwe Stehle

Senior Sales Manager
Institutional Sales
uwe.stehle@thieme.de
0049 711 8931 939